MonaLisa Touch®

TOUR DE FRANCE

Une présentation des Drs. Vahdat et Mouly, gynécologues obstétriciens à Paris

JEUDI 12 DÉCEMBRE
HYATT PARIS MADELEINE
20H

Conférence | Cocktail | Discussions

Retrouvez la Soirée-Conférence sur le laser MonaLisa Touch® à Paris !

Dr Christine Louis-Vahdat

DEKA Innate Ability

MonaLisa Touch®

L’auteur déclare n’avoir aucun conflit d’intérêt en rapport avec la présentation

INDICATIONS,CONTRE-INDICATIONS ET EFFETS SECONDAIRES DES LASERS CO2 EN RESTAURATION GENITALE

DOCTEUR Christine Louis-Vahdat

126, boulevard Saint Germain 75006 Paris

drcvahdat@aol.com

New Zealand Restricts All Transvaginal Mesh Im plants

from Radio New Zealand

Mesh Medical Device News Desk, December 12, 2017 ~ Whether petitioning Parliament, partaking in on-ca mera interviews or newspaper stories, anti-mesh ca mpaigners from around the world are seeing the resu lts of their efforts.

The new restrictions on transvaginal mesh implants are the result of greater awareness on the part of th e public and front-page news headlines.

New Zealand has gone one step further than any othe r country in its attitude toward the controversial polyp ropylene transvaginal mesh.

Early next year, New Zealand will restrict the use of all transvaginal mesh implants- those used to treat stress urinary incontinence (SUI) as well as pelvic organ prolapse (POP).

That means the small island nation is going one step further than its nearby neighbor, Australia, which announced last month, a ban on the use of mesh for POP only.

SIGN UP FOR MDND NEWSLETTER

Email Address

Preferred Format

HTML Text

Submit Form

CONTACT SHEILA BOSSIER FOR ANY TRANSVAGINAL MESH CONCERNS

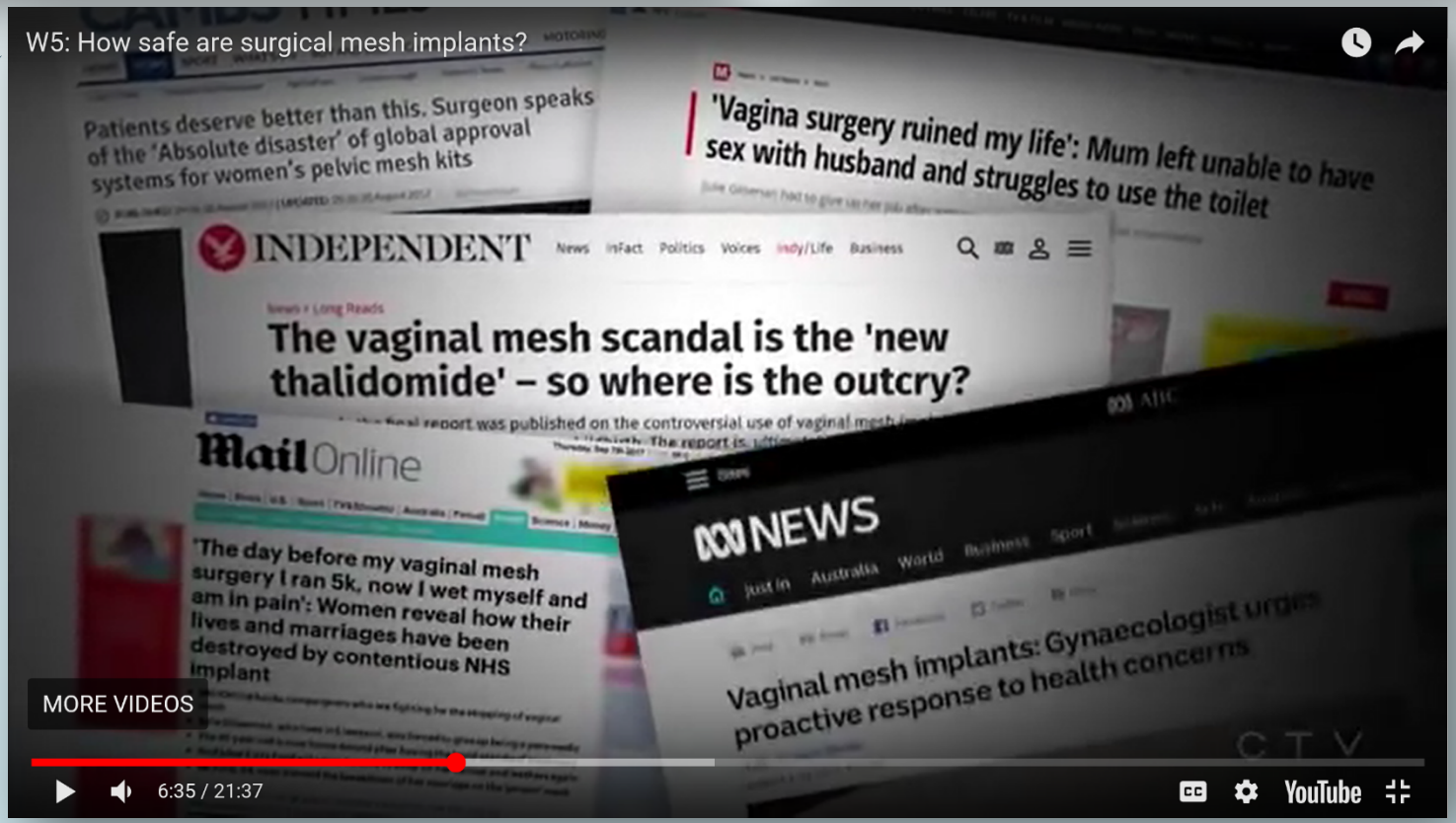

LES DEFINITIONS

L.A.S.E.R. :Light Amplification by Stimulated Emission of Radiation

il existe de multiples appareils qui permettent **d'émettre un rayon lumineux visible ou invisible** par l'œil humain.

On caractérise ces rayons de lumière en fonction **de leurs longueurs d'onde**.

Celles-ci s'étendent des rayons **ultraviolets** aux rayons **infrarouges** avec au milieu, les couleurs visibles de l'arc en ciel (**rouge**, **jaune**, **bleu**, **vert**, **violet**)

- **Si le rayon lumineux n'est composé que d'une longueur d'onde, il s'agit d'un laser.**

- **Les L.E.D (light emitting diode) : dispositif lumineux permettant d'obtenir un faisceau de longueur d'onde unique mais d'énergie très inférieure au laser.**

- Si il est composé de plusieurs longueurs d'onde, il s'agit alors d'une **lampe dite flash** (aussi appelée lumière intense pulsée).

Laser CO_2

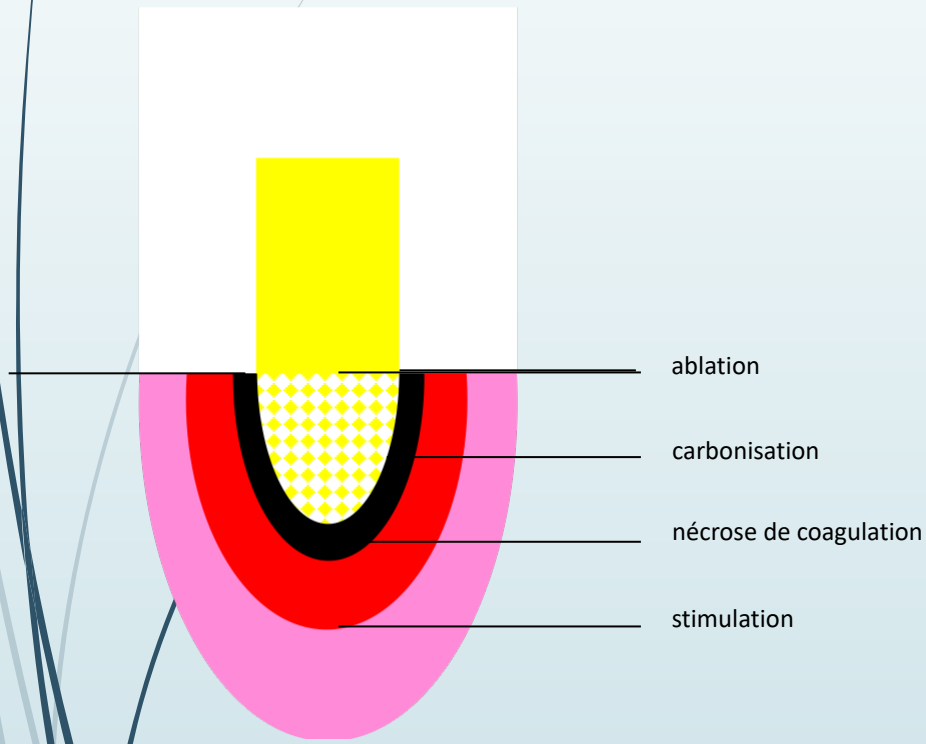

Ablation : élimine du tissu immédiatement

Carbonisation : une frange de tissu est fortement échauffée sans être vaporisée

Nécrose de coagulation : supplément de destruction cellulaire au-delà de l'ablation

Stimulation : régénère les tissus dans leur structure et leurs fonctions

1-3 μm 10 μm 20-3

Profondeur de pénétration dans l'eau des longueurs d'onde ablatives

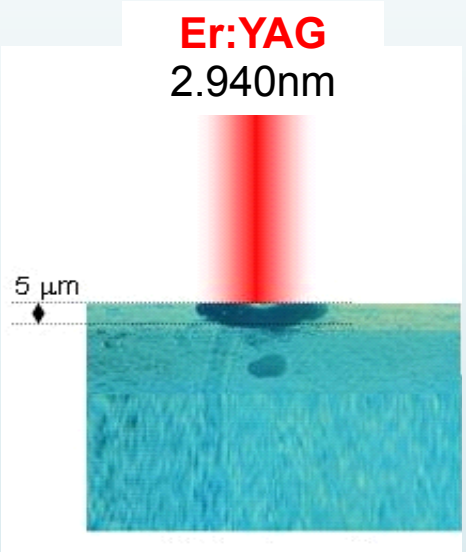

Absorption forte
Profondeur faible



Absorption 10x moins forte
Profondeur 10x plus grande

COMPARAISON DES PROFONDEURS DE PÉNÉTRATION

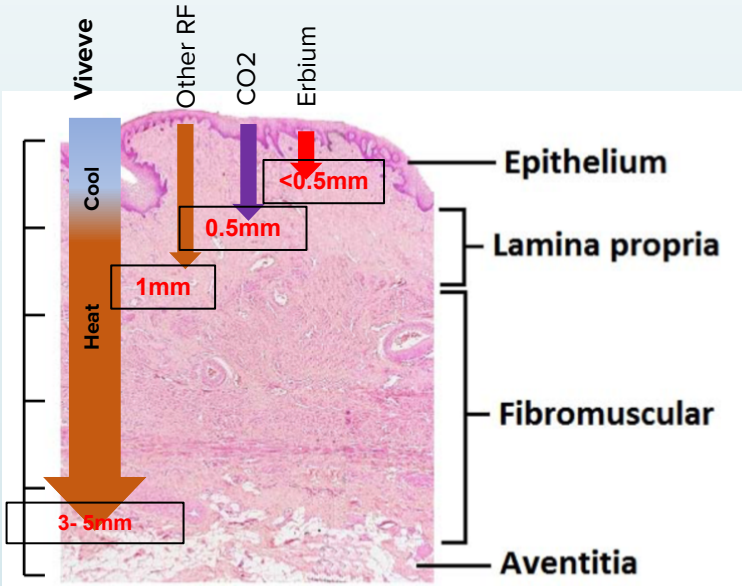

Vaginal Wall Cross Section

Les Lasers ont un effet ablatif peu profond

- Absorption de l'énergie par les tissus puis dispersion
- Effet direct sur la muqueuse
- **Pénétration uniquement jusqu'à la partie supérieure de la lamina propria**

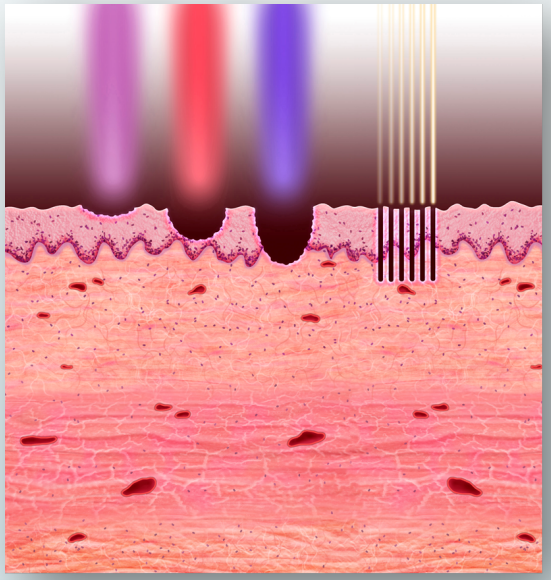

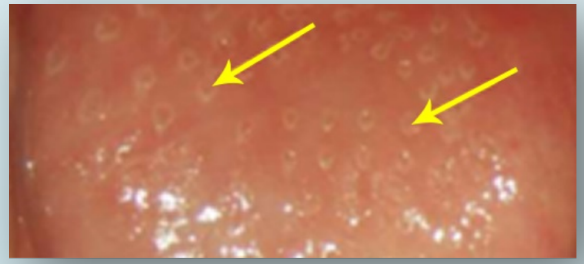

Impact sur le Tissu Muqueux

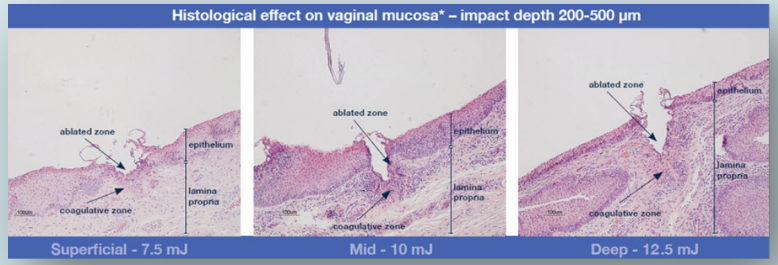

Mécanisme:

Effets dermiques connus de longue date par stimulation collagénique et remodelage

Application de ces effets à la muqueuse vaginale

- Risques peu importants
- Suites simples
- Techniques peu ou pas douloureuses

Berlin et al. A prospective study of fractional scanned nonsequential carbon dioxide laser resurfacing: a clinical and histopathologic evaluation. Dermatol Surg 2009

Tierney et al. Ablative fractionated CO2, laser resurfacing for the neck: prospective study and review of the literature. J Drugs Dermatol 2009

Tierney et al. Fractionated carbon dioxide laser treatment of photoaging: prospective study in 45 patients review of the literature. Dermatol Surg 2011

Ong et al. Fractional laser resurfacing for acne scars: a review. Br J Dermatol 2012

Iongo et al. Laser skin rejuvenation: epidermal changes and collagen remodeling evaluated by in vivo confocal microscopy. Lasers Med Sci 2013

L'action thermique du laser

*Active les fibroblastes de la muqueuse vaginale par l'effet thermique spécifique provoqué par l'irradiation

*Les fibroblastes retrouvent ainsi leur activité fonctionnelle et leur capacité de synthèse du collagène et de l'acide hyaluronique

*Réactivation des fibrocytes en fibroblastes fonctionnels.
La néo-collagénogénèse favorise l'élasticité, l'épaisseur et la résistance de la paroi vaginale

***LED LASER AH RF NE SONT PAS DES TRAITEMENTS de première itention des pathologies vulvovaginales* : SGUM, LSA, Vulvodynies, vaginisme etc…**

Mais doivent être intégrés dans une prise en charge pluridisciplinaire après avoir établi un diagnostic clinique rigoureux

Avis spécialisé
Biopsie
Oestrogéothérapie locale
Probiotiques
Dermocorticoïdes
Rééducation pelvi périnéale++++

Indications

- SGUM Syndrome génito-urinaire de la ménopause
- Incontinence urinaire, impériosité
- Relâchement vaginal)
- *LSA*
- *Incontinence urinaire*

Les bons gestes

- Examen préalable du col et du vagin au spéculum
- Rechercher des brides, lésions cervicales ou vaginales
- Vérifier la cicatrice de colpectomie si hysterectomie
- TV préalable permet d'évaluer la cavité vaginale et de situer le col d'où une introduction facilitée de la sonde
- Etre attentif au ressenti de la patiente pendant l'intervention
- Stopper l'acte si douleur
- Puissance diminuée au niveau de l'orifice vaginal qui est traité en dernier
- Prudence si colpectomie, brides ou cloisons vaginales
- Connaître les caractéristiques physiques du laser CO2 utilisé

Contre-indications

- Frottis anormal
- Infection urinaire et infection vulvovaginale active
- Grossesse
- Plaie cervicale ou vaginale
- Métrorragie
- Prolapsus > stade 2
- Bandelette sous urétrale perceptible au TV
- Douleurs pelviennes profondes
- ATCD Herpès traitement préventif

EFFETS SECONDAIRES

Sensation d’échauffement

Inflammation

Métrorragies

Augmentation de l’épaisseur de l’endomètre?

Sténose de l’urètre

MODE D'ACTION DES LASERS VAGINAUX CO2

Etude d'échantillons de muqueuse vaginale de femmes post ménopausées non hormonalement traitées au microscope électronique après laser fractionné CO2

Restauration des couches épithéliales, Augmentation du glycogène dans les cellules Modifications du chorion : restauration des fibroblastes, du collagène

Angiogenèse des papilles épithéliales

Stefano Salvatore and col ., Histological study on the effects of microablative fractional CO2 laser on atrophic vaginal tissue: an ex vivo study Menopause: The Journal of The North American Menopause Society Vol.22, No. 8, pp. 000/000 2015 by The North American Menopause Society*

Stefano Salvatore, A. Calligaro, Use of CO 2Laser Therapy Against Vaginal Atrophy, Vaginal Laxity and Urinary Incontinence. San Raffaele Hospital in Milan, Italy. University of Pavia, Italy (Doc interne Deka)

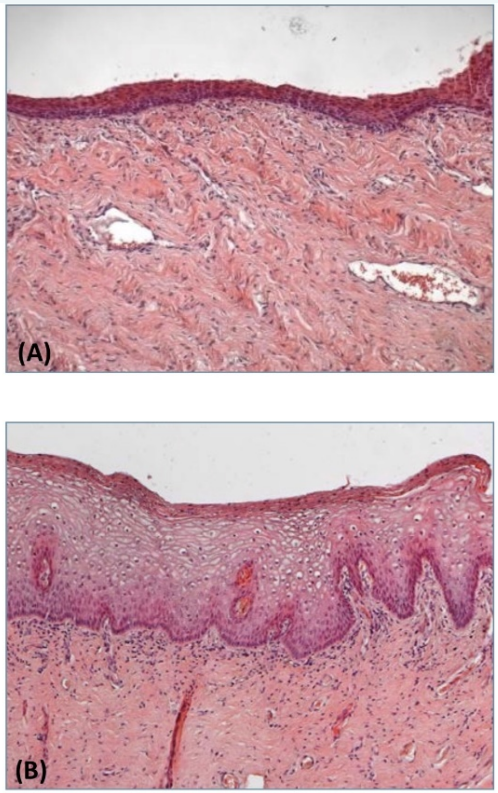

Figure 3.25 – Histological preparation of a section of the vaginal mucosa stained with haematoxylin and eosin (H&E). (**A**): Vaginal mucosa in the basal condition. This morphological picture indicates vaginal atrophy at an advanced stage with an epithelium formed by few cell layers and no papillae. (**B**): Vaginal mucosa of the same patient one month after the first session with the *MonaLisa Touch*® treatment. The much thicker epithelium and the larger diameter of epithelial cells rich in glycogen, demonstrate the restored metabolic trophism and dynamics of the whole epithelium.

LASER CO_2 FRACTIONNÉ

- Published 2018 Jan 19
- **Early Regenerative Modifications of Human Postmenopausal Atrophic Vaginal Mucosa Following Fractional CO_2 Laser Treatment**
- Biopsie vaginale 1 heure après la fin d'une séance: identification de l'action sur le tissu conjonctif par formation de nouveaux vaisseaux, de nouvelles papilles, de nouveau collagène et sur l'épithélium par desquamation des cellules de surface.

Stefano Salvatore,[1] Katlein França,[2] Torello Lotti,[3] Marta Parma,[1] Sonia Palmieri,[1] Massimo Candiani,[4] Edoardo D'Este,[5] Simona Viglio,[6] Antonia Icaro Cornaglia,[7] Aurora Farina,[7] Federica Riva,[7] Alberto Calligaro,[7] Jacopo Lotti,[8,*] Uwe Wollina,[9] Georgi Tchernev,[10] and Nicola Zerbinati[11]

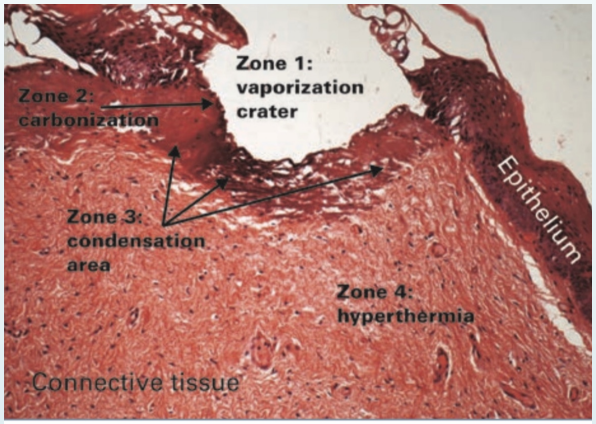

Figure 3.12 – Histological preparation of a section of the vaginal mucosa stained with haematoxy and eosin (*H&E*). As in figure 3.11, there are four different areas following the CO_2 fractior laser treatment *SmartXide² V²LR* CO_2. The light microscope does not show significant structu modifications in zone 4. It is possible to see the characteristic scallop-shaped aspect typical of t connective tissue of the vaginal mucosa.

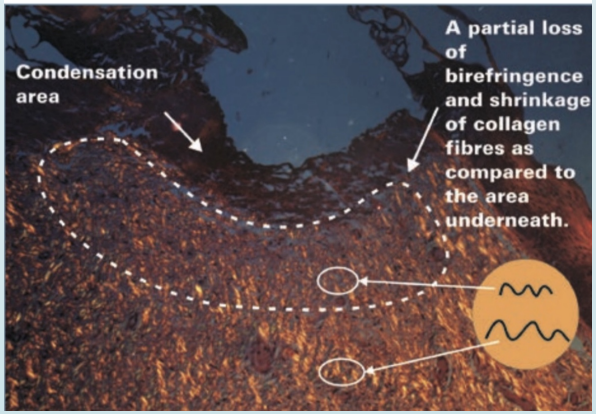

LASER CO_2 FRACTIONNÉ VAGINAL



Pièce à main à 360°

Dr Christine Louis-Vahdat

LASER CO2: les différentes pièces à main

Matériel :
Lunette de protection
Source LASER
Différentes PAM



ll range of available probes for HiScan V²LR. Simply changing th
dapted to all patient's needs. (**A**): Full-angle vaginal probe emittin
ne time. A single-use version will be ready in due course. (**B**): Si
2 versions are available with different diameter. (**C**): Single-mir
rnal terminal for the treatment of vulvar and perineal area.

DÉROULEMENT D'UNE SÉANCE TYPE: LASER VAGINAL

DÉROULEMENT D'UNE SÉANCE TYPE: LASER DE LA FOURCHETTE VULVAIRE

Aspect post traitement

RESPECT DES PRINCIPES DE BONNE PRATIQUE
Préambule à l'utilisation

Les objectifs cliniques sont atteints pour les praticiens qui pratiquent régulièrement

Bonne connaissance de l'anatomie de la région vulvo-vaginale

Intérêt de DU spécifiques

Signaler à son assureur l'utilisation de ces techniques, avenant au contrat de RCP

Démarche clinique rigoureuse, poser un diagnostic, évaluer le bénéfice de la méthode, informer la patiente

Délai de réflexion de 15 jours, consentement signé, devis signé

Résultats sur le SGUM (laser CO_2)

Indication	15 Séries (n > 1200)	1 Etude comparative	1 ECR
SGUM / atrophie vulvo-vaginale (sécheresse, brulures, dyspareunies)	Salvatore et al, Climacteric, 2014 & 2015 50 puis 77 femmes en échec d'estrogénothérapie Perino et al, Maturitas, 2015 48 femmes ménopausées Pagano et al, Menopause, 2016 26 Femmes après traitement d'un cancer du sein Pitsouni et al, Maturitas, 2016 53 femmes Filippini et al, Photomedecine Laser Surg, 2017 386 femmes Behnia-Willison et al, Eur J Obstet Gynecol Reprod Biol, 2017 102 femmes Siliquini et al, Climacteric, 2017 87 femmes	Pitsouni et al, Laser Med Sci, 2017 50 femmes Rétrospectif Cas / témoin 30 W vs 40W Pas de différence	Cruz et al, Menopause, 2017 45 femmes en 3 groupes ▪ Laser ▪ E2 loc ▪ Laser + E2 loc

Amélioration significative après 3 applications en 12 semaines

CONCLUSIONS

- Le manque d'étude randomisées rend difficile la méta-analyse des études et il n'y pas encore d'études force 1 concernant l'efficacité à long terme et les autres effets, négatifs ou positifs.

Des essais contrôlés randomisés comparant les traitements par laser par rapport au placebo aux médicaments ou aux hormones ou enfin à la chirurgie doivent être mis en place et sont nécessaires pour obtenir des preuves force 1

Pour atteindre l'EVIDENCE BASE MEDICINE, nécessité de nombreuses études randomisées vs placebo en double aveugle: elles sont en cours.

Photomedicine and Laser Surgery. – Vol. 35, No. 3, 2017.
Epub 2016 Dec 30– Vol. 26, No. 1, 2017. Epub 2016 Oct 09

Fractional CO_2 laser: from skin rejuvenation to vulvo-vaginal reshaping

Filippini M[1], Del Duca E[2], Negosanti F[2,3], Bonciani D[4], Negosanti L[5], Sannino M[2], Cannarozzo G[2], Nisticò SP[2,6]

1: Hospital State of Republic of San Marino - Republic of San Marino. 2: University of Rome Tor Vergata, Rome - Italy. 3: Dermatology Center, Bologna - Italy . 4: Piero Palagi University Hospital, Florence - Italy. 5: S.Orsola-Malpighi University Hospital, Bologna - Italy. 6: Magna Grecia University of Catanzaro - Italy .

Abstract

Background
The CO_2 laser has become the gold standard treatment in dermatologic surgery for the treatment of a large number of skin and mucosal lesions. The introduction of the fractional micro-ablative technology represented an integration to the ablative resurfacing technique, reducing the healing time and the side effects.

Objective
Vaginal rejuvenation performed with this technique is a minimally invasive procedure that stimulates internal tissues of the female lower genital tract to regenerate the mucosa, improving tissue trophism and restoring the correct functionality.

Methods
In our experience, 386 menopausal women affected with vulvo-vaginal atrophy (VVA) were treated with three section of fractional micro-ablative CO_2 laser.

Results
After three treatments, patients reported a complete improvement of the symptoms (59.94% dryness, 56.26% burn, sensation, 48.75% dyspareunia, 56.37% itch, 73.15% soreness, and 48.79% vaginal introitus pain).

Conclusions
Fractional micro-ablative CO_2 laser seems to reduce symptoms related to vaginal atrophy. The beneficial effects were reported just after the first session and confirmed 12 months after the last session.

386 patientes ménopausées
3T
Résultat à 12 mois

Amélioration
60% Sécheresse
56% Diminution des brûlures
73% diminution des douleurs

Climacteric – Vol. 19, No. 5, 2016. Epub 2016 Aug 2

The effect of microablative fractional CO_2 laser on vaginal flora of postmenopausal women

Athanasiou S[1], Pitsouni E[1,2], Antonopoulou S[3], Zacharakis D[1], Salvatore S[4], Falagas ME[2,5,6], Grigoriadis T[7]

1: National and Kapodistrian University of Athens, Athens – Greece. 2: AIBS, Athens – Greece. 3: "G. Gennimatas" General Hospital, Athens – Greece. 4: San Raffaele Hospital, Milan – Italy. 5: MSD General Hospital, Athens – Greece. 6: Tufts University School of Medicine, Boston, MA - USA. 7 : Alexandra Hospital", Athens - Greece.

Abstract

Objectives
To assess the effect of microablative fractional CO_2 laser ($MFCO_2$-Laser) therapy on the vaginal microenvironment of postmenopausal women.

Methods
Three laser therapies at monthly intervals were applied in postmenopausal women with moderate to severe symptoms of genitourinary syndrome of menopause, pH of vaginal fluid >4.5 and superficial epithelial cells on vaginal smear <5%. Vaginal fluid pH values, fresh wet mount microscopy, Gram stain and aerobic and anaerobic cultures were evaluated at baseline and 1 month after each subsequent therapy. Nugent score and Hay-Ison criteria were used to evaluate vaginal flora.

Results
Fifty-three women (mean age 57.2±5.4 years) participated and completed this study. $MFCO_2$-Laser therapy increased Lactobacillus ($p<0.001$) and normal flora ($p<0.001$) after the completion of the therapeutic protocol, which decreased vaginal pH from a mean of 5.5±0.8 (initial value) to 4.7±0.5 ($p<0.001$). The prevalence of Lactobacillus changed from 30% initially to 79% after the last treatment. Clinical signs and symptoms of bacterial vaginosis, aerobic vaginitis or candidiasis did not appear in any participant.

Conclusions
$MFCO_2$-Laser therapy is a promising treatment for improving the vaginal health of postmenopausal women by helping repopulate the vagina with normally existing Lactobacillus species and reconstituting the normal flora to premenopausal status.

53 patientes Augmentation des lactobacilles de 30 à 79%

Menopause – Vol. 23, No. 10, 2016

An assessment of the safety and efficacy of a fractional CO_2 laser system for the treatment of vulvovaginal atrophy

Sokol ER[1], Karram MM[2]

1: Stanford University, Stanford, CA - USA. 2: The Christ Hospital, Cincinnati, OH - USA.

Abstract

Objective
The aim of the study was to assess the safety and efficacy of a novel fractional CO_2 laser for the treatment of genitourinary syndrome of menopause (GSM).

Patients and Methods
Women presenting with GSM and meeting study criteria were enrolled. Examinations at baseline and follow-up (3 mo after final treatment) evaluated dilator tolerance and vaginal pH. Visual analog scales were used to assess pain, vaginal burning, vaginal itching, vaginal dryness, dyspareunia, and dysuria; Vaginal Health Index scores were completed before each treatment and at follow-up; Female Sexual Function Index and Short Form 12 questionnaires were also completed. Participant satisfaction was measured on a 5-point Likert scale (1=very dissatisfied, 5=very satisfied). Women received three laser treatments, 6 weeks apart.

Results
Thirty women participated (mean age 58.6±8.8 y). None withdrew or were discontinued due to an adverse event; three were lost to follow-up. Average improvement in visual analog scale scoring was 1.7±3.2 for pain, 1.4±2.9 for burning, 1.4±1.9 for itching, 6.1±2.7 for dryness, 5.1±3.0 for dyspareunia, and 1.0±2.4 for dysuria; improvement in average Vaginal Health Index and Female Sexual Function Index scores were statistically significant ($P<0.001$). Twenty-five of 30 participants (83%) showed increase in comfortable dilator size at 3-month follow up. Before the second and third treatments, 86.6% (26 of 30) of women reported they were better or much better than at the previous treatment; 26 of 27 women (96%) were reportedly satisfied or extremely satisfied at follow-up.

Conclusions
In this sample, the data suggest that the fractional CO_2 laser is effective and safe for treatment of the symptoms associated with GSM.

Menopause. Epub 2017 Feb 6

Use of a novel fractional CO_2 laser for the treatment of genitourinary syndrome of menopause: 1-year outcomes

Sokol ER[1], Karram MM[2]
1: Stanford University, Stanford, CA - USA. 2: The Christ Hospital, Cincinnati, OH - USA.

Abstract

Objectives
To assess safety and efficacy of a fractional CO_2 laser therapy for the treatment of genitourinary syndrome of menopause (GSM) with follow-up to 1 year posttreatment.

Methods
Women presenting with GSM and meeting inclusion criterion were enrolled. Visual Analog Scales were used to grade vaginal pain, burning, itching, dryness, dyspareunia, and dysuria. Dilators were used to rate vaginal elasticity at baseline and at each follow-up visit. Before each treatment and at follow-up, Vaginal Health Index scoring and Female Sexual Function Index questionnaires were completed. Women received three vaginal laser treatments spaced 6 weeks apart. Participant satisfaction was measured on 5-point Likert scales (1=very dissatisfied, 5=very satisfied).

Results
Of 30 women (mean age 58.6±8.8 years), three were lost to follow-up at 3 months and six at 1 year. None were discontinued or withdrew due to an adverse event. Average improvement in Visual Analog Scale scores for all symptom categories was statistically significant at 3 months and remained so through 1 year, except dysuria. Differences between data at 3 months and 1 year were not statistically significant, indicating persistence of positive outcomes. Average overall improvement in pain was 1.9 (±3.4), burning 1.9 (±3.1), itching 1.4 (±1.9), dryness 5.9 (±2.8), dyspareunia 4.9 (±3.3), and dysuria 0.9 (±3.1). Improvement in average Vaginal Health Index and Female Sexual Function Index scores was also statistically significant ($P<0.0001$). Of 19 women undergoing dilator examination at 1 year, 18 (94.8%) were comfortable with the same or larger dilator size. Twenty-two of 24 women (92%) were satisfied or extremely satisfied with the treatment at 1 year.

Conclusions
Based on study data up to 1 year, the fractional CO_2 laser may be an effective and safe treatment for women suffering from symptoms of GSM, although additional studies with larger populations and placebo control is needed to confirm these results.

3 traitements à 6 semaines d'intervalle

30 patientes
92% satisfaites à 1 an
Evaluation de l'élasticité
94% à 1 an

European Journal of Obstetrics Gynecology and Reproductive Biology
Vol. 213, 2017. Epub 2017 Apr 2

Safety and long-term efficacy of fractional CO_2 laser treatment in women suffering from genitourinary syndrome of menopause

Behnia-Willison F[1,2], Sarraf S[3], Miller J[4], Mohamadi B[1], Care A S[4,5], Lam A[6], Willison N[2], Behnia L[7], Salvatore S[8]
1: FBW Gynaecology Plus - Australia. 2: Flinders University – Australia. 3: Virginia Women's Center – USA. 4: The University of Adelaide – Australia. 5: Robinson Research Institute – Australia. 6: Centre for Advanced Reproductive Endosurgery – Australia. 7: University of Tehran – Iran. 8: San Raffaele Hospital – Italy.

Abstract

Objective
To evaluate the safety and long-term efficacy of fractional CO_2 laser treatment in reducing the severity of symptoms of genitourinary syndrome of menopause (GSM) in menopausal women.

Study Design
102 women presenting with symptomatic GSM were treated with the fractional CO_2 laser (MonaLisa Touch, DEKA) system across a series of treatments delivered at intervals of six or more weeks. The Australian Pelvic Floor Questionnaire was used to gather data on sexual function and side-effects at three time-points across the study period (prospective panel design study). Wilcoxon signed-rank tests were used to detect statistically and clinically significant changes in sexual function and side-effects occurring from pre- to post-treatment. The primary outcome of this study was an improvement of the symptoms of GSM. The secondary outcome included bladder function and prolapse symptoms.

Results
A total of 102 women suffering from moderate to severe GSM were recruited. Eighty-four percent experienced significant improvement in their symptoms after CO_2 laser treatment. Scores on measures of sexual function, dyspareunia, and bothersomeness of sexual issues were improved from pre-treatment to long-term (12–24 month) follow-up. Furthermore, there were improvements on measures of bladder function ($P = 0.001$), prolapse ($P = 0.001$), vaginal sensation ($P = 0.001$), vaginal lubrication ($P < 0.001$) and urge incontinence ($P = 0.003$) from the pre-treatment assessment to the second assessment (i.e. after the third treatment).

Conclusions
In this study, fractional microablative CO_2 laser treatment was associated with an improvement in symptoms of GSM and sexual function.

102 patientes
évaluation de la fonction sexuelle
84% satisfaites entre T1 et T2

Climacteric – Epub 2017 May 15

Fractional CO_2 laser therapy: a new challenge for vulvovaginal atrophy in postmenopausal women

Siliquini GP[1], Tuninetti V[2], Bounous VE[2], Bert F[3], Biglia N[2]
1: Sedes Sapientiae Institute, Turin - Italy. 2: Umberto I Hospital, University of Turin, Turin - Italy. 3: University of Turin, Turin - Italy.

Abstract

Objectives
To evaluate the effects of CO_2 laser in the treatment of vulvovaginal atrophy (VVA) in postmenopausal women.

Methods
VVA was assessed in 87 postmenopausal women (mean age 58.6 ± 6.9 years) before and after the treatment. The protocol consisted of three monthly treatments and included the treatment of vulva. Subjective measures included VAS (Visual Analog Scale) both for vaginal dryness and dyspareunia; DIVA (Day-by-day Impact of Vaginal Aging); a questionnaire on treatment satisfaction and one about the degree of pain during the procedure. Objective measures included VHI (Vaginal Health Index) and VVHI (Vulvo-Vaginal Health Index). Time points of the study were at the screening visit (T0), at baseline (T1), at week 4 (T2), at week 8 (T3), after 3 months since the last laser application (T4), after 6 months (T5), after 9 months (T6), after 12 months (T7) and after 15 months (T8).

Results
Treatment induced significant improvement in the VAS score. After treatment, VHI and VVHI indicated no VVA and this improvement was long lasting. Multivariate analysis showed that the time of follow-up was correlated with better VHI and VVHI ($p < 0.001$). DIVA improved over time ($p < 0.001$).

Conclusions
This study shows that CO_2 laser treatment induces a significant and long-lasting improvement of symptoms.

87 patientes

87 patientes âge moyen 58,6

3 Traitements à 1 mois avec traitement vulvaire

A 12 et 15 mois

Amélioration significative de l'AVV

Evaluation VHI et VVHI / VAS (sécheresse et Dyspareunie)

Maturitas - Epub 2017 Jul 21

CO_2-laser for the genitourinary syndrome of menopause. How many laser sessions?

Athanasiou S[1], Pitsouni E[1], Falagas ME[2,3], Salvatore S[4], Grigoriadis T[1]
1: Alexandra Hospital, National and Kapodistrian University of Athens, Greece.
2: Alfa Institute of Biomedical Sciences (AIBS), Athens – Greece. Henry-Dunant Hospital Center, Athens – Greece.
3: Tufts University School of Medicine, Boston, MA –USA. 4: San Raffaele Hospital, Milan – Italy.

Abstract

Objectives
The aim of this prospective study was to assess the efficacy of 3, 4 or 5 CO_2-laser sessions for the management of the genitourinary syndrome of menopause (GSM).

Methods
Postmenopausal women with moderate to severe symptoms of dyspareunia, wanting to resume/retain sexual activity, were treated with 3–5 laser sessions depending on symptom severity/presence, sexual function, clinical findings and women's preference following the third laser application.

Main Outcomes
Severity of dyspareunia, dryness, sexual function, sexual satisfaction and frequency of sexual intercourse defined the primary outcomes. Vaginal Maturation Value (VMV) and Vaginal Health Index Score (VHIS) defined the secondary ones.

Results
Fifty-five women received three sessions, 53 an extra fourth and 22 an extra fifth. Following the third, fourth and fifth laser sessions, respectively: dyspareunia completely regressed in 15/55 (27%), 32/55 (58%) and 38/47 (81%) of participants; dryness completely regressed in 20/55 (36%), 36/55 (66%) and 44/51 (86%); normal sexual function resumed in 23/55 (41%), 37/54 (69%) and 41/49 (84%); VMV regained non-atrophic values in 29/55 (53%), 38/55 (69%) and 42/50 (84%); and VHIS regained non-atrophic values in 44/55 (80%), 53/55 (96%) and 55/55 (100%) of participants.

Conclusion
Results of this study indicate that CO_2-laser therapy may contribute to complete regression of dyspareunia and dryness and reestablishment of normal sexual function in postmenopausal women, in a dose-response manner. An extra fourth or fifth session may further increase the GSM symptom-free rate.

55 PATIENTES 3T
53 PATIENTES 4T
22 PATIENTES 5T

Dyspareunie	27%/58%/81%
Sécheresse	36%/66%/86%
VMV	53%/69%/84%
VHIS	80%/96%/100%

Menopause – Epub 2017 Jul 31

Randomized, double-blind, placebo-controlled clinical trial for evaluating the efficacy of fractional CO_2 laser compared with topical estriol in the treatment of vaginal atrophy in postmenopausal women

Cruz VL, Steiner ML, Pompei LM, Strufaldi R, Fonseca FLA, Santiago LHS, Wajsfeld T, Fernandes CE
ABC School of Medicine, São Bernardo do Campo, São Paulo – Brazil.

Abstract

Objective
The aim of the study was to evaluate efficacy of fractional CO_2 vaginal laser treatment (Laser, L) and compare it to local estrogen therapy (Estriol, E) and the combination of both treatments (Laser + Estriol, LE) in the treatment of vulvovaginal atrophy (VVA).

Methods
A total of 45 postmenopausal women meeting inclusion criteria were randomized in L, E, or LE groups. Assessments at baseline, 8 and 20 weeks, were conducted using Vaginal Health Index (VHI), Visual Analog Scale for VVA symptoms (dyspareunia, dryness, and burning), Female Sexual Function Index, and maturation value (MV) of Meisels.

Results
Forty-five women were included and 3 women were lost to follow-up. VHI average score was significantly higher at weeks 8 and 20 in all study arms. At week 20, the LE arm also showed incremental improvement of VHI score (P=0.01). L and LE groups showed a significant improvement of dyspareunia, burning, and dryness, and the E arm only of dryness (P<0.001). LE group presented significant improvement of total Female Sex Function Index (FSFI) score (P=0.02) and individual domains of pain, desire, and lubrication. In contrast, the L group showed significant worsening of pain domain in FSFI (P=0.04), but FSFI total scores were comparable in all treatment arms at week 20.

Conclusions
CO_2 vaginal laser alone or in combination with topical estriol is a good treatment option for VVA symptoms. Sexual-related pain with vaginal laser treatment might be of concern.

Etude comparative Laser seul, Laser+Estriol et Estriol seul
45 patientes
L et L+E nette amélioration E amélioration sécheresse seul symptôme

Lasers Med Sci - Epub 2017 Aug 2

Microablative fractional CO_2 laser for the genitourinary syndrome of menopause: power of 30 or 40 W?

Pitsouni E[1], Grigoriadis T[1], Falagas M[2,3], Tsiveleka A[1], Salvatore S[4], Athanasiou S[1]
1: Alexandra Hospital, National and Kapodistrian University of Athens, Greece.
2: Alfa Institute of Biomedical Sciences (AIBS), Athens – Greece. Henry-Dunant Hospital Center, Athens – Greece.
3: Tufts University School of Medicine, Boston, MA –USA. 4: San Raffaele Hospital, Milan – Italy.

Abstract

This retrospective case-control study aimed to compare 30 versus 40 W power of CO_2 laser for the therapy of genitourinary syndrome of menopause (GSM). Postmenopausal women with severe intensity of dyspareunia and dryness were eligible to be included in this study. Primary outcomes were dyspareunia and dryness. Secondary outcomes were itching/burning, dysuria, frequency and urgency, Female Sexual Function Index (FSFI), vaginal maturation value (VMV), and Vaginal Health Index Score (VHIS).

One laser therapy was applied every month for 3 months. Outcomes were evaluated at baseline and 1 month following the 3rd therapy. Fifty (25 per group) women were included in this study. In the 30-W group, mean improvement of dyspareunia, dryness, itching/burning, FSFI, VMV, and VHIS was 6.1 ± 1.7, 6.0 ± 1.9, 5.9 ± 2.0, 16.6 ± 6.7, 29.9 ± 13.0, and 11.0 ± 2.9, respectively (within group comparisons all $p < 0.001$). In the 40-W group, mean improvement of dyspareunia, dryness, itching/burning, FSFI, VMV, and VHIS was 6.1 ± 1.7, 6.5 ± 2.0, 5.2 ± 2.5, 14.8 ± 7.1, 25.0 ± 13.4, and 10.5 ± 4.1, respectively (within-group comparisons, all $p \leq 0.001$).

Comparison between 30 and 40 W revealed that mean improvement or presence of all GSM symptoms and clinical signs was not statistically significant different. CO_2 laser therapy may improve GSM symptoms and clinical signs. This improvement did not seem to associate to power of 30 or 40 W.

50 patientes: 25 +30W 25+40W

Pas d'impact sur l'efficacité

Archives of Gynecology and Obstetrics – Epub 2017 Sep 2

Long-term reliability of fractioned CO_2 laser as a treatment for vulvovaginal atrophy (VVA) symptoms

Pieralli A[1], Bianchi C[1], Longinotti M[1], Corioni S[1], Auzzi N[1], Becorpi A[1], Fallani MG[1], Cariti G[1], Petraglia F[1]

1: Careggi University Hospital, Florence - Italy.

Abstract

Purpose
The aim of this study was to evaluate long-term effects of the fractional CO_2 laser for the treatment of vulvovaginal atrophy (VVA) symptoms.

Methods
Women presenting with VVA symptoms and meeting inclusion criterion were enrolled to fractioned CO_2 laser therapy. Patient's satisfaction was measured on five-point Likert scale at 4 weeks and 6, 12, 18, 24 months after treatment by interview and clinical examination for vaginal livability.

Results
184 patients constituted the final study group: 128 women were spontaneous menopause and 56 were oncological menopause. 117 women were nulliparous and 36 had previous hysterectomy. 95.4% (172/184) of the patients declared that they were satisfied or very satisfied with the procedure at 4 weeks after treatment. At 6 months 92% (170/184) patients were satisfied; at 12 months 72% (118/162) were satisfied; at 18 months 63% (60/94) were satisfied; at 24 months 25% (4/16) of patients answered they were still satisfied. We observed a decline in patient's satisfaction between 18 and 24 months after laser therapy. Data showed that the time interval from onset of menopause was a statistically significant factor ($p < 0.05$) for treatment satisfaction in oncological group.

Conclusions
Long-term data showed that the improvement of vaginal health may continue up to 24 months after fractional CO_2 laser treatment although between 18 and 24 months benefits decline, and approximately 80% of women decide to start a new treatment cycle of laser applications.

184 patientes
128 ménopausées
56 Cancer du sein hormono dépendant

Satisfaction des patientes à 6,12,18 et 24 mois +T3

95,4% T3+4 semaines

92% T3+6 mois

72% T3+12 mois

63% T3+18 mois

>18 mois 80% font un nouveau traitement

122 PATIENTES

Multicentrique rétrospective

Lasers Surg Med. Epub 2017 Sep 7

Fractional CO_2 laser of the vagina for genitourinary syndrome of menopause: Is the out-of-pocket cost worth the outcome of treatment?

Lang P[1], Dell JR[2], Rosen L[3], Weiss P[4], Karram M[1].
1: The Christ Hospital, Cincinnati, OH - USA. 2: Institute for Female Pelvic Medicine, Knoxville, TN - USA.
3: Fairfax OB-GYN Associates, Gainesville, VA - USA. 4: Roxbury Surgical Center, Beverly Hills, CA - USA.

Abstract

Objectives
The purpose of this study is to assess patient's satisfaction treatment outcomes and out-of-pocket expense for the fractional CO_2 laser (SmartXide) in the treatment of genitourinary symptoms of menopause (GSM).

Materials and Methods
A multicenter retrospective cohort study of patients who completed a course of three vaginal treatments with the SmartXide Fractional CO_2 laser. Patients contacted via telephone and asked to participate in questionnaires to evaluate for adverse outcomes since last treatment, symptom severity before and after treatment, patient satisfaction with treatment, patient satisfaction with out-of-pocket expense, and sexual function.

Results
Of the 368 patients contacted, 122 agreed to be interviewed. No patients reported seeking emergent medical treatment. Patient reported vaginal dryness significantly improved following treatment ($P<0.05$). The frequency of intercourse increased from "once a month" to "few times a month" ($P<0.001$). The vast majority of patients reported being satisfied with their treatment results (86%) and with the cost of treatment (78%). Satisfaction with the out-of-pocket expense did not correlate with household income ($P=0.07$).

Conclusions
The SmartXide Fractional CO_2 laser is a safe and efficacious treatment for GSM. This treatment is associated with a high level of patient satisfaction with both treatment results and out-of-pocket expense.

Aucune douleur pendant le traitement
Satisfaction 86%

A. PERINO1, G. CUCINELLA2, G. GUGLIOTTA3, S. SAITTA4, S. POLITO5, B. ADILE2, R. MARCI5, G. CALAGNA1**Eur**opean **Rev**iew for **Med**ical and **Pharmacol**ogical **Sci**ences2016; XX: xxxx-xxxx

- Patientes « Vessie hyperactive »: depuis ≥3 mois, ≥8 mictions/24H avec au moins 3 ou 4 épisodes d'urgence avec ou sans incontinence, pendant 3 jours
- Etude pilote observationnelle prospective de janvier 2014 à Janvier 2015 **avec 30 patientes**
- Evaluation de l'urgence : 0, pas d'urgence, urgence légère 2, urgence modérée; **3, urgence sévère**; **4, incontinence par urgence** (Patient's Perception of Intensity of Urgency Scale)
- Seules les patientes **3 et 4** sont enrollées dans l'étude
- Traitement :3 séances de Laser Mona Lisa(DEKA) espacées de 4 semaines

Pitsouni E, Grigoriadis T, Falagas ME, Salvatore S, Athanasiou S Laser therapy for the genitourinary syndrome of menopause.
A systematic review and meta-analysis. Maturitas. 2017 Sep;103:78-88.

- Cette revue systématique et méta analyse a pour but **de synthétiser tous les résultats** concernant l'efficacité des lasers concernant le GSM (avec ou sans I U) en date d'Octobre 2016 :**14** études ont été retenues incluant **542 patientes**

- **Sécheresse, dyspareunie, prurit, brûlure , dysurie, urgenturies, fréquence urinaire et IU** diminuent de façon de manière significative et constante dans toutes les publications disponibles.

- En conclusion la thérapie laser semble avoir un avenir prometteur pour ces femmes en ***réduisant la sévérité de leurs symptômes, en augmentant leur qualité de vie, en restaurant leur muqueuse vaginale au statut pré ménopausique***.

Cependant manquent encore les arguments "évidence base médicine"

LASER FRACTIONNÉ CO_2 : Expérience

« Gynécologie, obstétrique fertilité et sénologie » Christine Louis-Vahdat, Isabelle Jardin,Henri Azaïs

Service de chirurgie et oncologie gynécologique et mammaire, Pitié-Salpêtrière, AP-HP, Médecine Sorbonne Université, Paris, France

Comment je fais… un traitement des sècheresses vaginales induites par la ménopause par LASER vaginal fractionné au CO_2

- *En cours, étude multicentrique Service de chirurgie et oncologie gynécologique et mammaire, Pitié-Salpêtrière, AP-HP, Médecine Sorbonne Université, Paris, France*

[b]Universitary Hospital Ernani Polydoro São Thiago HU-UFSC, Federal University of Santa Catarina, R. Profa. Maria Flora Pausewang, s/n - Trindade, Florianópolis, SC CEP-88036-800, Brazil

* Corresponding author at: Rua Vidal Ramos nº 100, Tubarão, Santa Catarina CEP 88701160, Brazil.
E-mail addresses: otto.feurschuette@unisul.br, drottomay@gmail.com (O. Feuerschuette), anacancelier1970@gmail.com (A. Cancelier), sheila.silveira@yahoo.com.br (S. Silveira), jeffripe@rocketmail.com (J. Pereira).

Received 26 June 2017

http://dx.doi.org/10.1016/j.ejogrb.2017.07.008

Re: "Safety and long-term efficacy of fractional CO_2 laser treatment in women suffering from genitourinary syndrome of menopause" [Eur. J. Obstet. Gynecol. Reprod. Biol. 213 (2017) 39–44]

Dear Editor,

We read with interest the recent study by Behnia-Willison and colleagues [1] in your June issue, reporting their investigation of "*the safety, feasibility and long-term efficacy (12–24 months) of fractional micro-ablative CO_2 treatment in a cohort of postmenopausal women suffering dyspareunia and/or other symptoms due to GSM* [genitourinary syndrome of menopause]". Their study included 102 postmenopausal women (median age 61 years; range: 51–86) who had three fractional CO_2 vaginal laser treatments at intervals of six or more weeks because they "*were not responding or not able to take conventional treatments (such as œstrogen therapy for postmenopausal women).*" Each woman had a colposcopy before laser treatment to grade the vaginal atrophy. Before and after the treatment, the women completed the Australian Pelvic Floor Questionnaire [2]. All variables improved significantly, including sexual function, painful intercourse, vaginal dryness, and reduced libido.

The results of this single-centre study are very encouraging, especially in view of the scarcity of the literature about GSM treatment by vaginal laser. We would like to share our experience and difficulties and discuss some points raised by this study.

From December 2016 to May 2017, we treated 45 women in a similar but substantially narrower age bracket (median age 54 years; range 48–60). They all presented with very similar symptoms due to GSM; this is less likely to be entirely the case in a population aged from 51 to 86 years.

Our pre-laser clinical screening systematically included a gynecologic examination, a cervical (Pap) smear test followed by a colposcopy only in case of abnormalities, a transvaginal ultrasound examination to measure the endometrial thickness, and a vaginal pH time of 1000 μs, DOT spacing 1000 μm, and SmartStak with parameter 2 for the first two treatments and parameter 3 for the third. The vaginal probe, introduced without lubricant, is used to treat the entire vaginal wall, then the vestibule, and the fourchette. Sexual intercourse is strongly discouraged during the three days after treatment.

After the first laser treatment, our patients had global improvement for urinary function, especially in terms of urge and stress incontinence, and a decrease of vaginal discharge. They reported an improvement of overall quality of intercourse after the third treatment. To date, we have not been faced with any complication. Moreover, the transvaginal ultrasound examination performed before each laser treatment did not reveal any increase of endometrial thickness in any of our cases.

Our patients are very motivated; none has been lost to follow-up. However, the use of laser treatment is still limited, perhaps because it is not yet widely known by women, but probably more because laser treatments are not currently covered in France by the national health insurance fund. Further research is needed to assess safety and effectiveness of this innovative treatment in correctly selected patients.

Conflict of interest

None.

Funding sources

None.

References

[1] Behnia-Willison F, Sarraf S, Miller J, Mohamadi B, Care AS, Lam A, et al. Safety and long-term efficacy of fractional CO_2 laser treatment in women suffering from genitourinary syndrome of menopause. Eur J Obstet Gynecol Reprod Biol 2017;213:39–46.
[2] Baessler K, O'Neill SM, Maher CF, Battistutta D. Australian pelvic floor questionnaire: a validated interviewer-administered pelvic floor questionnaire for routine clinic and research. Int Urogynecol J Pelvic Floor Dysfunct 2009;20:149–58.
[3] Bachmann GA, Cheng RJ, Rovner E. Vulvovaginal com-plaints. In: Lobo RA, editor. Treatment of the postmenopausal woman: basic and clinical aspects. 3rd ed. Burlington, MA: Academic Press; 2007. p. 263–70.

Christine Louis-Vahdat*
126, Boulevard Saint-Germain, 75006 Paris, France

Sonia Gaucher[a,b]
[a]Université Paris Descartes, Paris Sorbonne Cité, 75006 Paris, France
[b]Service de chirurgie générale, plastique et ambulatoire, AP-HP, HUPC, Hôpital Cochin, 75014 Paris, France

* Corresponding author.
E-mail address: drcvahdat@aol.com (C. Louis-Vahdat).

Received 22 June 2017
Accepted 6 July 2017

Efficacité du Laser C02

De nombreuses études montrent l'efficacité du laser C02 fractionné

- Perino et col. publient en 2015 une étude sur 48 patientes ayant subi trois séances de laser vaginal CO2 fractionné. Les résultats montrent une différence significative pour les symptômes d'atrophie vulvo-vaginale suivants : sècheresse vaginale, brulures, irritations et dyspareunie ((P<0.0001)). Les niveaux du score vaginal (VHI de Bachmann) étaient significativement augmentés dès la première séance (P<0.0001). 91% des patientes s'estimaient satisfaites ou très satisfaites sur une échelle de qualité de vie validée.
- Aucun effet secondaire n'était relevé

Perino A, Calligaro A, Forlani F, Tiberio C, Cucinella G, Svelato A, Saitta S, Calagna G, Vulvo-vaginal atrophy: A new treatment modality using thermo-ablative fractional CO2 laser. Maturit s. 2 0 1 5 Mar;80(3):296-301. doi:10.1016/j.maturitas.2014.12.006. Epub2014 Dec 25.

*David Elia, **Atrophie vulvovaginale et Laser Fractionné CO2.** Genesis N°183 (mars/avril 2015)*

Dr Christine Louis-Vahdat

Je vous remercie

drcvahdat@aol.com

MERCI DE VOTRE ATTENTION

Retrouvez nous sur nos réseaux !

DEKA
Innate Ability

MonaLisa Touch®